STRATEGIES FOR SCOLIOSIS SURGERY:

Some adolescents with scoliosis may have progressive curvatures which may reach a threshold where surgery is the best option. Adults can have scoliosis too. Adults may have a degenerative type of scoliosis, or it may be a childhood scoliosis which then became painful or progressed as an adult and had an additional degenerative etiology as well. Well-known strategies for scoliosis treatment, which is common for all treating surgeons, are to halt the progression of the curvature. In most cases, surgeons also try to safely realign the spine and make it straighter. This has the advantage of preventing degeneration of the remaining discs below the fusion. Dr. Buttermann has shown this experimentally (1). This biomechanical study showed that by correcting the scoliosis, the intradiscal pressure and biomechanics of the disc below the surgically-treated region had a more normal and uniform profile that minimized the peak stresses which are known to potentially cause damage to the disc.

Dr. Buttermann has a spinal deformity practice that is unique and differs in a number of ways from other surgeons in three broad categories. First, his philosophy is to perform motion-preserving surgery using techniques that still achieve the desired deformity correction and pain relief. He also uses low-profile instrumentation, and avoids radiation to his patients which is especially important in young females due to the high risk of cancer.

Motion-preserving surgery can be total disc replace for one and two level degenerative conditions. In young childhood scoliosis patients, it means using temporary implants such as expandable rods or tethers, to realign the spine in the growing child. In the mature child, adolescent, or adult it means highly selective fusion of only the absolutely necessary vertebral motion segments to achieve clinical curve correction. Dr. Buttermann performs the surgery on as few levels as possible so as to preserve spinal motion. It is very important to minimize the number of levels fused in the lumbar spine, as this is where most of the mobility and function of the spine arise from (2,3). For scoliosis affecting the thoracic spine, a thoracic fusion works well. Since there is little motion in the thoracic spine, thoracic fusion does not lead to any function deficit (Fig. 1). Classic teaching for double major curvature, large thoracic and lumbar curve, was to fuse both curves down to the lower lumbar spine or even to the sacrum and pelvis. However, often one can do a selective fusion. This entails fusing the thoracic spine and correcting its curvature. The lumbar spine is a secondary curve and will correct to varying degrees on its own, and thus one can preserve mobility in the lumbar spine. Dr. Buttermann trained in both pediatric and adult deformity patients. During his training he saw numerous patients who had had surgery of both thoracic and lumbar curves during childhood and were returning as adults because of problems below the 15 to 20 year-old fusion area. Typically these were young adult females who had had scoliosis surgery as a teenager down to the L3 or L4 level. They were now in their late 20s and early 30s and returning for evaluation because of severe incapacitating low back pain. The pain was due to accelerated deterioration of the remaining lumbosacral discs below the old fusion (Fig. 2). This is a crucial time for these young female adults, as they are either trying to start a family, starting or trying to advance their career. To have to take time off from their family and career for lower lumbar spine surgery can be extremely difficult for a family. This repeatedly seen conditions lead to Dr. Buttermann's philosophy is that even patients who did not qualify for a traditional selective thoracic fusion was to treat the thoracic levels and leave the lumbar curvature relatively untouched. This has been Dr.

Buttermann's philosophy for 25 years, and during this time aggressive selective rather than total spinal fusion, only 17% of patients had spinal fusion of the lumbar spine. Although the lumbar spine has an obvious residual scoliosis, these patients function at high levels (Fig. 3). They have not had to interrupt their career or alter their family planning. The 17% which then did require fusion distally have also done well; however, they are very stiff, and the lack of lumbar flexibility affects many aspects of their activities of daily living and prevents certain recreational activities.

In the adult patient, Dr. Buttermann also advocates a selective technique to avoid long constructs just as he does in the pediatric population. Here again, the strategy is to preserve motion and maximize function. For double major scoliosis, this procedure entails the standard thoracic spinal fusion with correction of the thoracic curve, but in the lumbar curve, he only fuses the apical segment, leaving motion above and below the apex of the lumbar curve (Fig. 4). For thoracolumbar curves, he also only fuses the apical vertebral segments (Fig. 5). Dr. Buttermann's outcomes have been highly satisfactory. Although it does not change the normal aging of the adjacent discs, the surgery has not aggravated the degeneration of the lumbosacral level discs, which is known to occur uniformly in the adult when fused from the thoracic spine all the way down to L3 - L5.

Another concern has to do with the size and profile of the instrumentation. Dr. Buttermann's philosophy is that more metal is *not* better in scoliosis surgery. He has performed studies demonstrating reduced muscle injury by using low-profile instrumentation (4,5). Additionally, in the smaller child, instrumentation which is prominent can be palpably painful and in some cases can also be unsightly, as the screw heads can be seen below and tenting the skin. Dr. Buttermann's strong belief in using low-profile instrumentation has actually led to his designing and patenting a low-profile screw construct system. It is also important to note that by using the appropriate technique, one can minimize the number of segments which are instrumented. Many competitors use "all pedicle screw constructs" which entails putting 2 screws in every vertebra ("high density construct") and then performing a derotation maneuver. This technique results in satisfactory correction of the scoliosis, but unfortunately produces a thoracic "flat back" (6,7). Flat back, or the elimination/loss of the normal thoracic kyphosis (and normal lumbar lordosis) was one complication of the vintage "Harrington" straight-rod techniques and now has reappeared with the all screw constructs. The problems with loss of thoracic kyphosis cannot be over-stated as it leads to junctional kyphosis, increased rate of adjacent disc degeneration, and decreased lung volume and pulmonary function (8,9,10,11). An intimate knowledge of spine biomechanics allows Dr. Buttermann to improve thoracic kyphosis and still use a screw construct (Fig. 6).

Additional concerns with all pedicle screw constructs besides thoracic flat back and prominent instrumentation include difficult assessment of the fusion status due to so many screws creating metal artifact, and high costs related to so many implants. But the greatest concern is the insidious danger to the patient related to radiation. This is directly related to inserting so many screws that requires excessive x-ray radiation. Dr. Buttermann uses surgical techniques that minimize the use of radiation. This is especially important, as many scoliosis patients are young females, and radiation to the breast and pelvic tissue at an early age has a relatively high risk of cancer. Dr. Buttermann has a mature perspective of the benefits vs risks of radiation which

reflects his training and experience. Even during the era of hook constructs, young female scoliosis patients had increased risk of breast and pelvic cancer secondary to radiation (12,13). Now, in the "all screw" era, multiple x-rays are obtained for *every* screw inserted by some surgeons. The reasons vary but often has to do with surgeons not having sufficient training in spinal anatomy for deformity cases. To get around this lack of understanding the anatomy, intraoperative CT scan (O-arm) is being vigorously promoted by some surgeons. Recent studies have shown that the amount of radiation from intraoperative CT is 40 times greater than conventional techniques (14). Despite these known risks, these surgeons persist in their technique that uses all screws via intra-operative CT guidance.

Dr. Buttermann listens to his patients, they want the procedure where they maintain motion and function with a clinically straight spine, acceptable cosmesis (reduced rib hump, level shoulders, smaller incision) and superior long-term outcomes (Fig. 7). Dr. Buttermann provides solutions by using innovative techniques combined with over 20 years experience.

References

1. Buttermann GR, Beaubien BP. *In vitro* disc pressure profiles below scoliosis fusion constructs. Spine 33(20):2134-42, 2008.
2. Udoekwere UI, Krzak JJ, Graf A, Hassani S, Tarima S, Riordan M, Sturm PF, Hammerberg KW, Gupta P, Anissipour AK, Harris GF. Effect of Lowest Instrumented Vertebra on Trunk Mobility in Patients with Adolescent Idiopathic Scoliosis Undergoing a Posterior Spinal Fusion. Spine Deform. 2014 Jul;2(4):291-300.
3. Lee MC, Õunpuu S, Solomito M, Smith BG, Thomson JD. Loss in spinal motion from inclusion of a single midlumbar level in posterior spinal fusion for adolescent idiopathic scoliosis. Spine 2013 Oct 15;38(22):E1405-10.
4. Buttermann GR, Thorson TM, Mullin WJ. Outcomes of Posterior Facet versus Pedicle Screw Fixation of Circumferential Fusion: A Cohort Study. Eur Spine J. 23(2): 347-355, 2014.
5. Buttermann GR, Mullin WJ, Thorson TM. Posterior Lumbar Muscle Changes Related to Prominence of Posterior Instrumentation in Spinal Fusion. 30th Annual Minnesota Orthopaedic Society Meeting, Minneapolis, MN, May 8, 2014.
6. Fletcher ND, Hopkins J, McClung A, Browne R, Sucato DJ. Residual thoracic hypokyphosis after posterior spinal fusion and instrumentation in adolescent idiopathic scoliosis: risk factors and clinical ramifications. Spine 2012 Feb 1;37(3):200-6.
7. Vora V, Crawford A, Babekhir N, Boachie-Adjei O, Lenke L, Peskin M, Charles G, Kim Y. A pedicle screw construct gives an enhanced posterior correction of adolescent idiopathic scoliosis when compared with other constructs: myth or reality. Spine 2007 Aug 1;32(17):1869-74.
8. Hassanzadeh H, Gupta S, Jain A, El Dafrawy MH, Skolasky RL, Kebaish KM. Type of Anchor at the Proximal Fusion Level Has a Significant Effect on the Incidence of Proximal Junctional Kyphosis and Outcome in Adults After Long Posterior Spinal Fusion. Spine Deform. 2013 Jul;1(4):299-305.
9. Shen J, Lin Y, Luo J, Xiao Y. Cardiopulmonary Exercise Testing in Patients with Idiopathic Scoliosis. J Bone Joint Surg Am. 2016 Oct 5;98(19):1614-1622.

10. Matsumoto H, Colacchio ND, Schwab FJ, Lafage V, Roye DP, Vitale MG. Flatback Revisited: Reciprocal Loss of Lumbar Lordosis Following Selective Thoracic Fusion in the Setting of Adolescent Idiopathic Scoliosis. Spine Deform. 2015 Jul;3(4):345-351.
11. Helgeson MD, Shah SA, Newton PO, Clements DH 3rd, Betz RR, Marks MC, Bastrom T. Evaluation of proximal junctional kyphosis in adolescent idiopathic scoliosis following pedicle screw, hook, or hybrid instrumentation. Spine 2010 Jan 15;35(2):177-81.
12. Ronckers CM, Land CE, Miller JS, Stovall M, Lonstein JE, Doody MM. Cancer mortality among women frequently exposed to radiographic examinations for spinal disorders. Radiat Res. 2010 Jul;174(1):83-90.
13. Simony A, Hansen EJ, Christensen SB, Carreon LY, Andersen MO. Incidence of cancer in adolescent idiopathic scoliosis patients treated 25 years previously. Eur Spine J. 2016 Oct;25(10):3366-3370.
14. Nelson EM, Monazzam SM, Kim KD, Seibert JA, Klineberg EO. Intraoperative fluoroscopy, portable X-ray, and CT: patient and operating room personnel radiation exposure in spinal surgery. Spine J. 2014 Dec 1;14(12):2985-91.

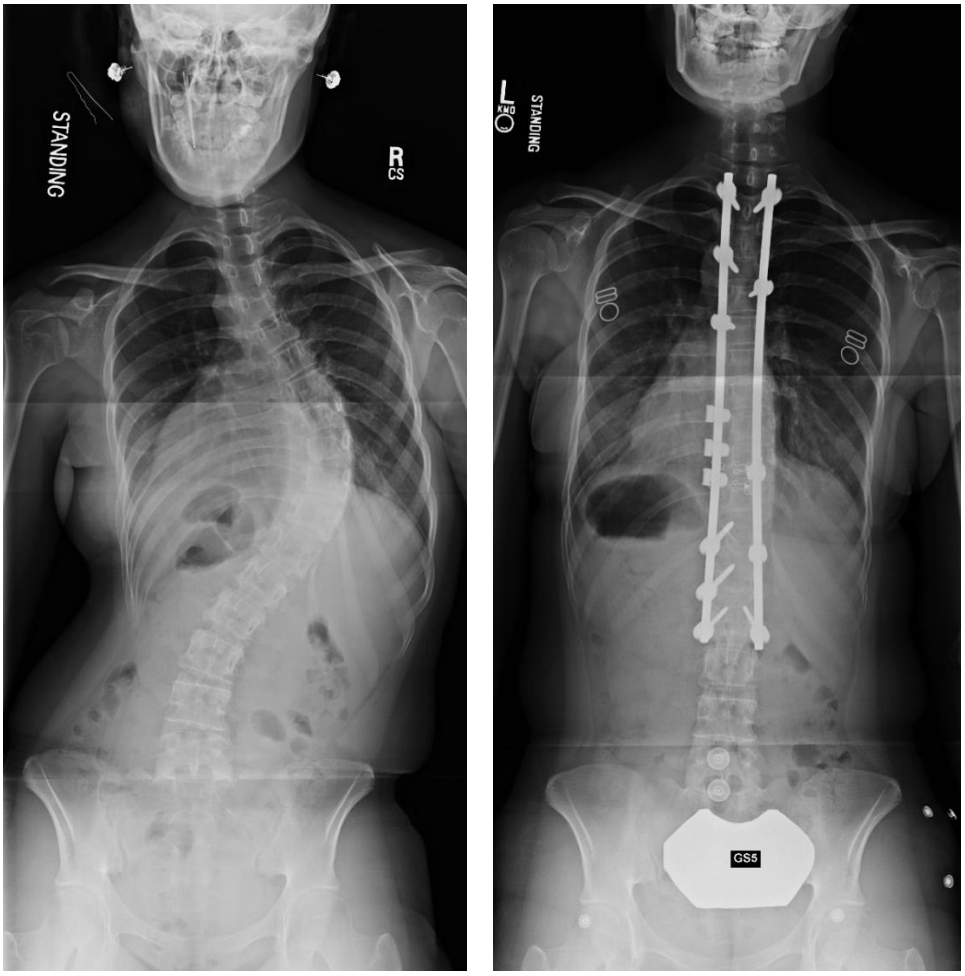

Fig. 1. Preoperative (left) and postoperative (right) traditional posterior thoracic spinal fusion for scoliosis using minimal implant density and low-profile screws in an adolescent by Dr. Buttermann.

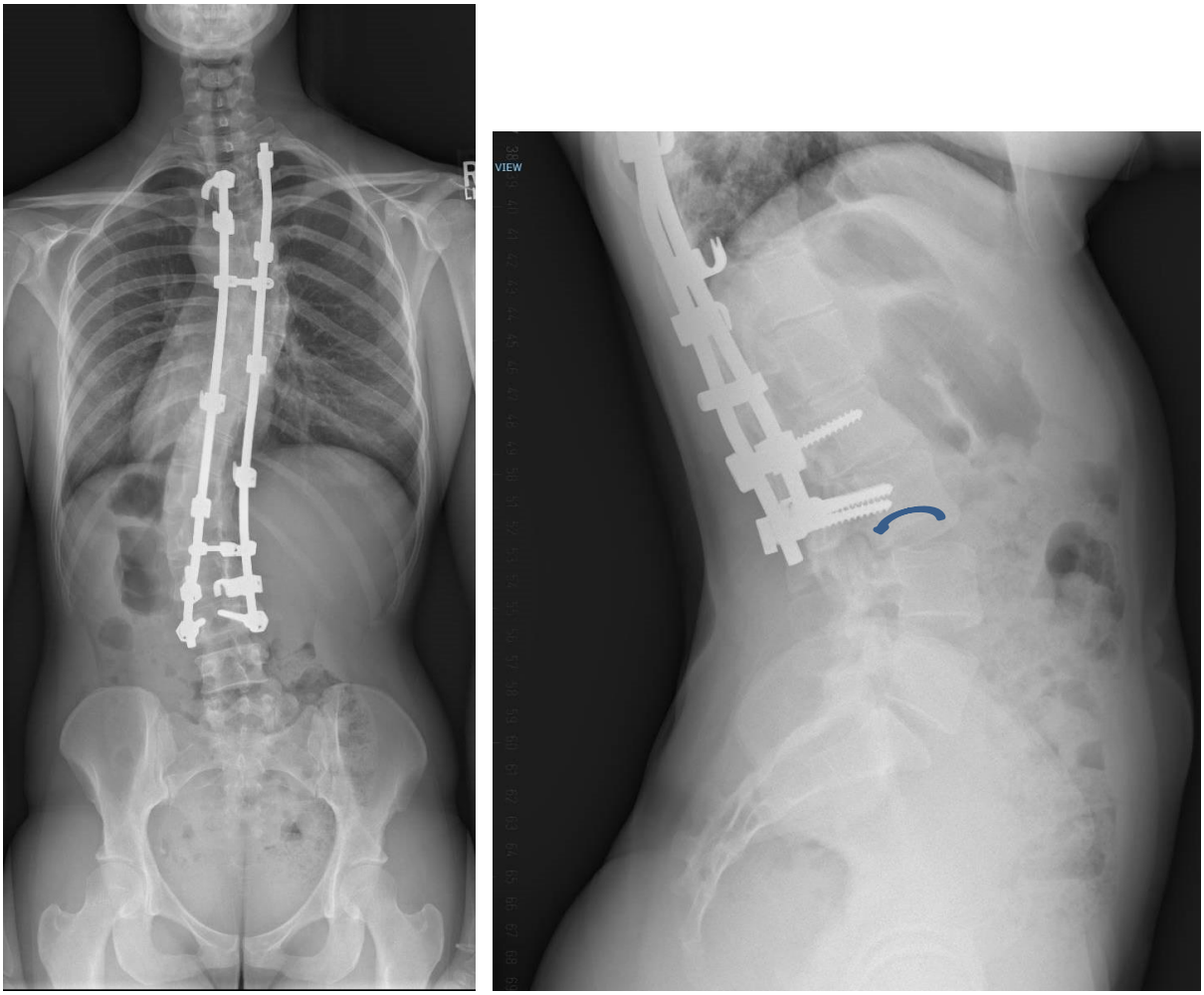

Fig. 2. This adolescent female had scoliosis posterior fusion performed by a well know pediatric orthopaedic surgeon in a neighboring city. Unfortunately, a lack of exposure to adults with spinal deformity resulted in this patient being fused down to L3. She could have been fused to L1 and prevented the adjacent L34 retrolisthesis and instability pain that prevents her from doing any sports 14 years after her surgery.

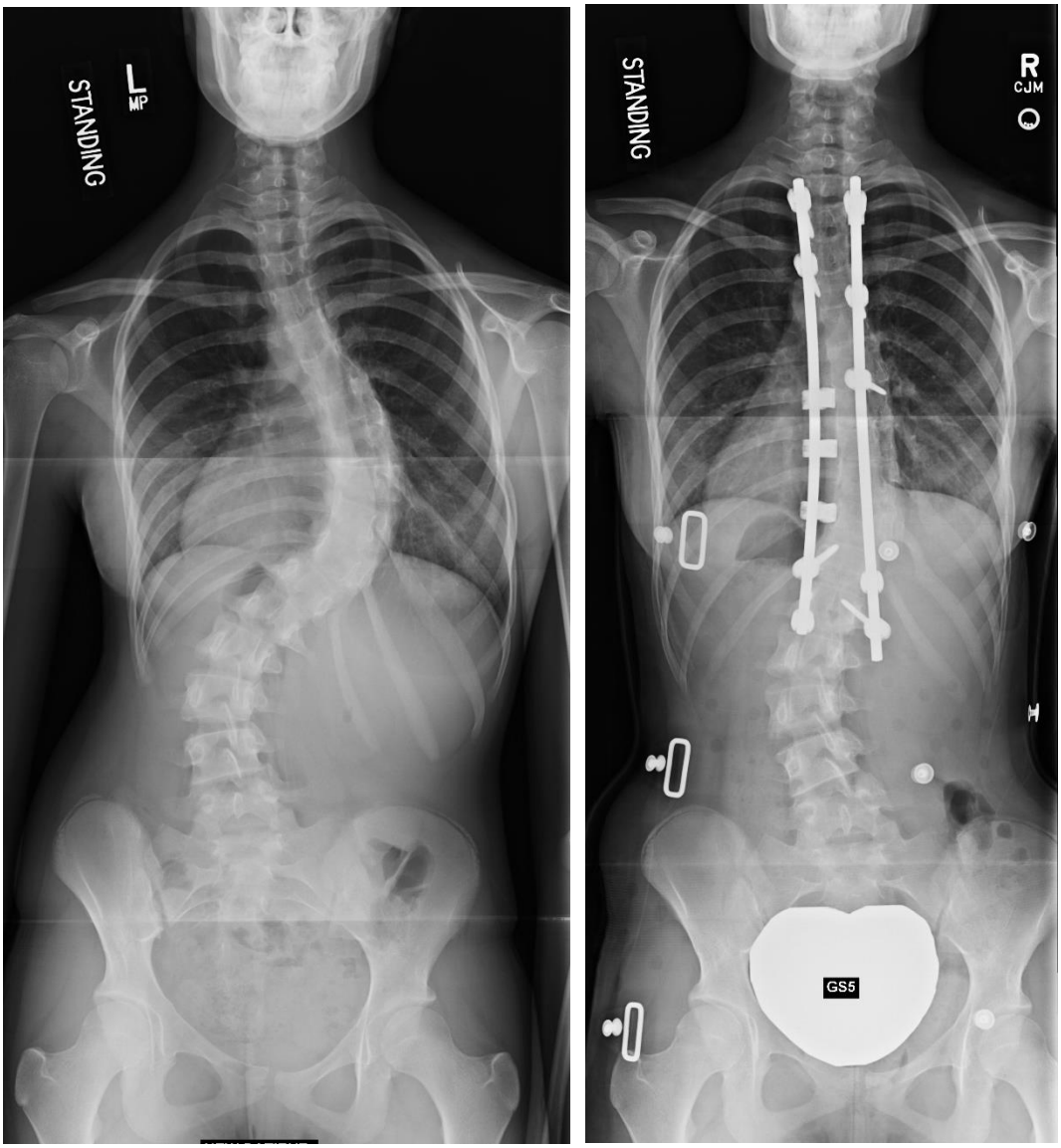

Fig. 3. This adolescent scoliosis patient with major curvature of both thoracic and lumbar spine was told by another surgeon that she needed to have her fusion all the way down to L4. She saw Dr. Buttermann who offered her motion preserving scoliosis surgery; he did a selective thoracic fusion (the lumbar curve was not fused. She has no pain and normal mobility of the lower spine. At 10 year follow-up, only 17 percent of Dr. Buttermann's patients with this type of scoliosis have subsequently gone on to have the lumbar curve fused.

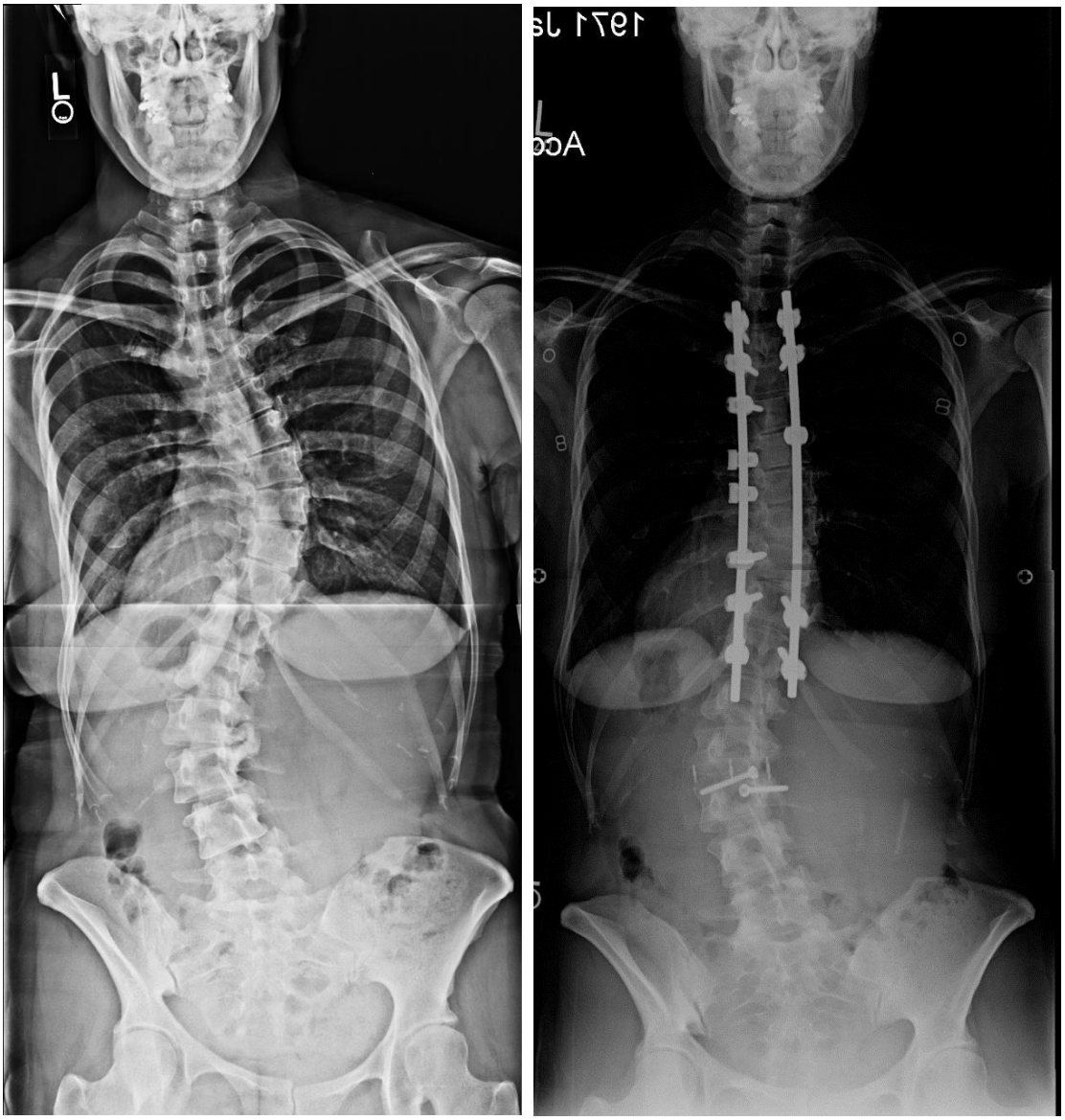

Fig. 4. Adult scoliosis patient who was told by another surgeon she needed fusion all the way down to L5 or S1. Dr. Buttermann did a selective thoracic fusion and a single level lumbar fusion at the apex of the lumbar curve. The patient enjoys normal lumbar range of range of motion.

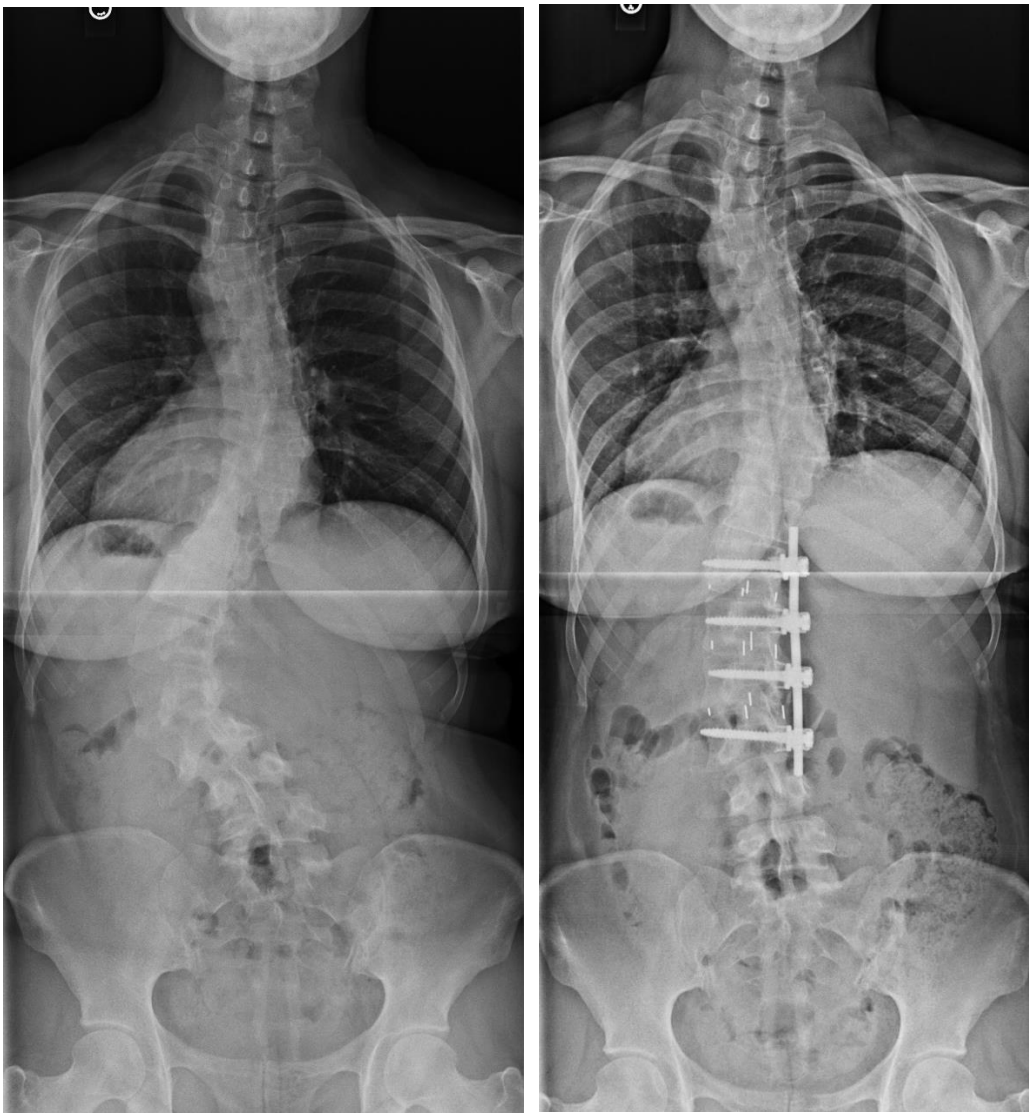

Fig. 5. Adult scoliosis patient who was told by another surgeon she needed fusion all the way down to L5. Dr. Buttermann did a selective thoraco-lumbar apical fusion. The patient enjoys near normal lumbar range of range of motion.

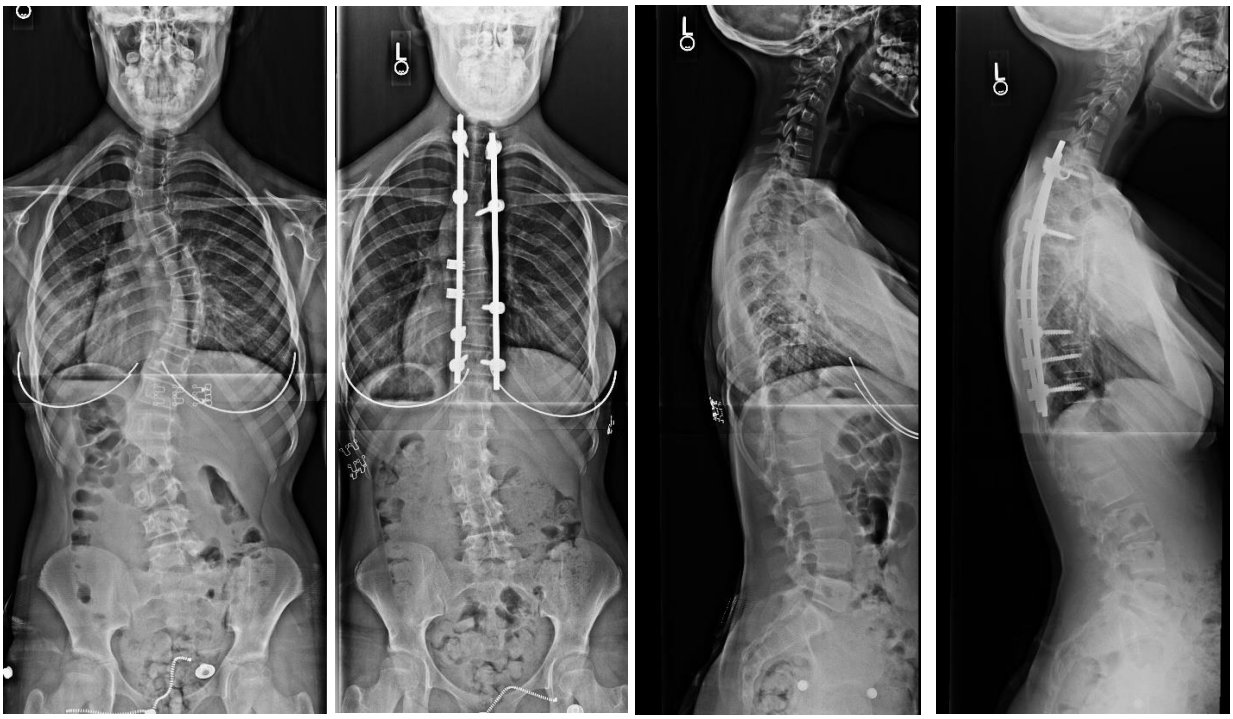

Fig. 6. Adolescent scoliosis patient treated by Dr. Buttermann. The images on the left are pre- and postoperative frontal xrays which show scoliosis correction. Sagittal images on the right show that the patient started with a lordotic thoracic spine and demonstrate recreation of a normal thoracic kyphosis with surgery.

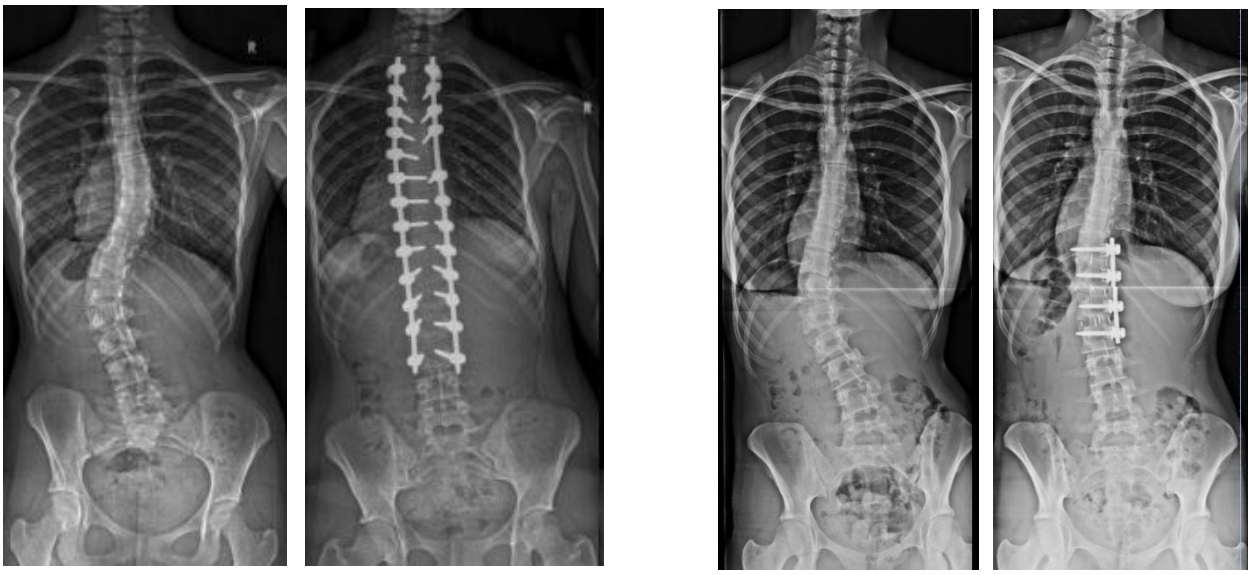

Fig. 7. Adolescent scoliosis patients. The patient on left had a high density all pedicle screw construct by a spine surgeon in an adjacent community. The patient on the right had surgery with Dr. Buttermann who did a selective thoraco-lumbar apical fusion. The patient enjoys the desired near normal lumbar range of range of motion and completely normal function including sports.